

See discussions, stats, and author profiles for this publication at: <https://www.researchgate.net/publication/366466028>

Journal of Medical Case Reports and Case Series Guillain–Barré Syndrome and vasculitis–like changes following severe acute respiratory syndrome coronavirus 2 Vaccination, chemother...

Article · December 2022

CITATIONS

0

READS

689

3 authors, including:



[Ute Krüger](#)

Active Health

21 PUBLICATIONS 2,151 CITATIONS

[SEE PROFILE](#)



[Elisabet Englund](#)

Lund University

331 PUBLICATIONS 18,881 CITATIONS

[SEE PROFILE](#)

Guillain-Barré Syndrome and vasculitis-like changes following severe acute respiratory syndrome coronavirus 2 Vaccination, chemotherapy, and Rituximab

Krüger Ute^{1*}, Martin Hubert², Englund Elisabet³

¹Department of Clinical pathology, Country Hospital, 39185 Kalmar, Sweden

²Department of Neuropathology, Charité University Medicine Berlin, 10117 Berlin, Germany

³Department of Clinical Sciences, Lund University, 22100 Lund, Sweden

*Corresponding Author: Krüger Ute, Department of Clinical pathology, Country Hospital, 39185 Kalmar, Sweden.

Received date: 12 September 2022; Accepted date: 27 September 2022; Published date: 30 September 2022

Citation: Ute K, Hubert M, Elisabet E (2022) Guillain-Barré Syndrome and vasculitis-like changes following severe acute respiratory syndrome coronavirus 2 Vaccination, chemotherapy, and Rituximab. J Med Case Rep Case Series 3(14): <https://doi.org/10.38207/JMCRCS/2022/DECB031403103>

Copyright: © 2022 Krüger Ute. This is an open-access article distributed under the terms of the Creative Commons Attribution License, which permits unrestricted use, distribution, and reproduction in any medium, provided the original author and source are credited.

Abstract

Vaccines have long been suggested to be a cause of autoimmune diseases. This report describes the case of a lymphoma patient in his 60's who developed both Guillain-Barré syndrome (GBS) and vasculitis-like changes after being vaccinated twice against severe acute respiratory syndrome coronavirus 2 (SARS-CoV-2). The patient received rituximab and chemotherapy due to the recurrence of lymphoma. The patient subsequently developed liver failure and GBS and ultimately died. Histopathologically, myeloradiculitis, encephalitis, peripheral neuritis, cerebral vasculitis-like changes with fresh cerebral infarctions, and liver necrosis were detected.

In summary, this report may help initiate consideration of guidelines for vaccination against SARS-CoV-2, in patients receiving chemotherapy in combination with rituximab.

Keywords: Pathology, GBS, Vaccine, Vasculitis, SARS-CoV-2

Introduction

Background

In the Coronavirus disease 2019 (COVID19) pandemic, which has peaked but does not yet seem to be over, it is important to consider possible unwanted side effects of the SARS-CoV-2 vaccination. This relates, in particular, to the combination of chemotherapy in individuals with pre-existing malignant conditions and various degrees of immunological weakness. Vaccination against SARS-CoV-2, while generally recommended, is particularly advised for people with malignant conditions. Chemotherapy combined with rituximab is a recognized treatment for lymphoma, and rituximab is used in the treatment of several chronic, including rheumatic,

illnesses. The combination of rituximab therapy and the SARS-CoV-2 vaccine is described in the literature as questionable since the immune system is weakened by the therapeutic anti-CD20 antibody [1]. Immunologic disorders such as Guillain-Barré syndrome (GBS) [2,3] and vasculitis [4-13] have been seen to develop after vaccination against SARS-CoV-2. Additionally, immunocompromised individuals undergoing treatment for malignant or other severe illnesses may have a higher risk than others to be affected by such disorders, "perhaps" particularly in association with anti-viral vaccination.

Case Presentation

A disease-burdened man in his 60s died in hospital and was referred for clinical autopsy. The patient had several malignancies diagnosed during the last six years. Among other conditions, the man was noted to have thyroid cancer treated with a total thyroidectomy, prostate cancer treated with prostatectomy, and follicular B-cell lymphoma. The lymphoma recurred and required treatment repeatedly. A few months before death, the patient received several cytostatic treatments, the last four chemotherapy periods in combination with rituximab.

Between two treatment periods, the patient received two doses of Pfizer/BioNTech's SARS-CoV-2 vaccine, at a one-month interval. The patient was initially recovering from the lymphoma, imaging techniques showed a decrease in tumor volume. However, a few days after the last chemotherapy session and two months after the second vaccination, the patient was admitted to the hospital with an acute infection. He developed liver failure and GBS soon after. Physicians observed acute polyneuropathy with weakness in the arms and legs and bilateral facial palsy. The patient died one month after admission (three months after the second vaccination) due to liver failure and pronounced axonal polyneuropathy.

Histopathologically, the patient had extensive liver necrosis. As a morphological substrate of GBS, massive radiculitis was seen.

Investigations

Electroneurography and cerebrospinal fluid examinations were performed, confirming the patient's GBS.

At autopsy, the macroscopic investigation revealed changes indicative of liver failure: a 2,300 g enlarged yellowish-green liver, 800 ml of ascites, 400 ml of pleural effusion on each side, and 90 ml of pericardial effusion. Histopathologically, the examiner observed confluent centrilobular necrosis and pronounced, centrally accentuated intra- and extracellular cholestasis. The kidneys exhibited cholestatic nephropathy with intratubular bile casts. The spleen was slightly enlarged, as were the axillary, tracheobronchial, and iliac lymph nodes. Microscopically, however, there were no remnants of the follicular B-cell lymphoma or any other malignancy.

Additionally, the histological picture of cerebral vasculitis-like changes with fresh cerebral and brain stem infarctions was found.

The brain weighed 1,500 g. Macroscopically, there were signs of mild edema but no focal lesions. Histopathologically, the examiner noted lymphoid perivascular cell infiltrates in the frontally and temporally region (**Figure 1A-D**) and the medulla oblongata. In the corpus callosum and medulla oblongata, the examiner found focal vasculitis-like changes with surrounding fresh brain infarcts measuring up to 4 mm in diameter (**Figure 2A-B**). A vasculitis was not possible to show with confirmatory stains, since the material was fully used in the primary stainings, before special stainings and immunochemical stainings could be applied.

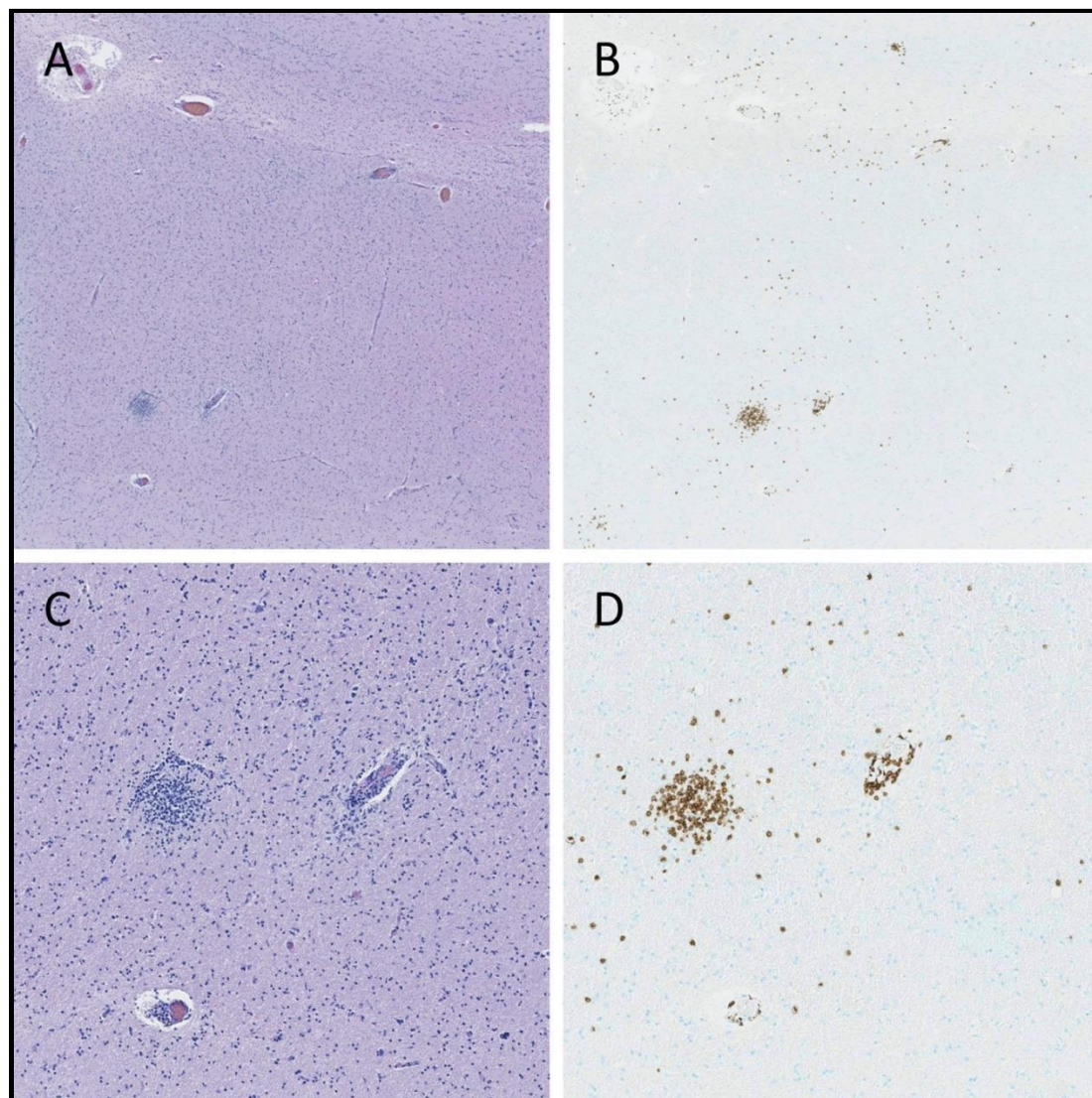


Figure 1. Histopathological images of the temporal lobe: Scattered T-lymphocyte infiltrates near vessels.

- A. Routine staining HE, 25 x magnification
- B. Immunological staining CD3 (brown), 25 x magnification
- C. Routine staining HE, 70 x magnification
- D. Immunological staining CD3 (brown), 70 x magnification

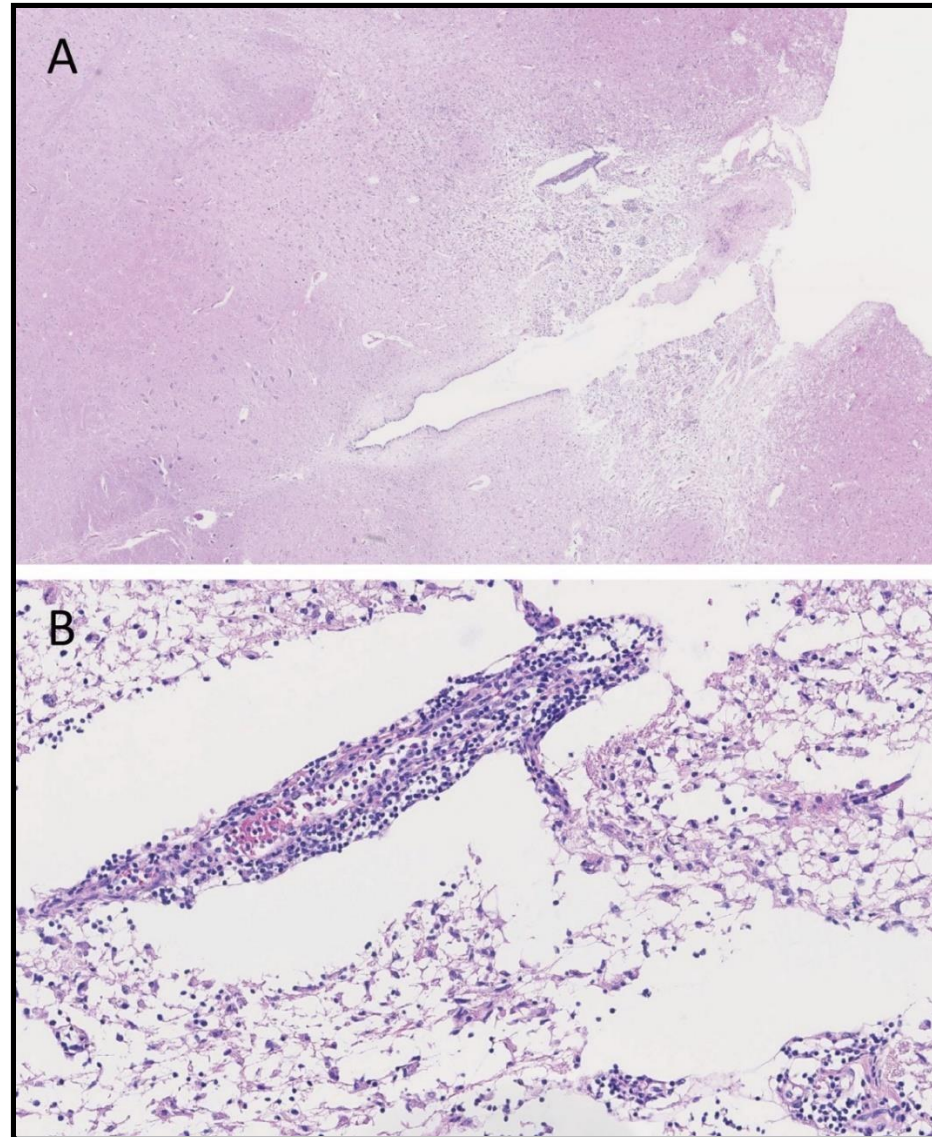


Figure 2. Histological images of the medulla oblongata: Vasculitis-like changes with surrounding fresh brain infarcts.
 A. Routine staining HE, 18 x magnification
 B. Routine staining HE, 140 x magnification

Due to the clinical condition of GBS, the spinal cord, adjacent radicular nerves, and axillary nerves were assessed. Histopathologically, a dense lymphoid infiltrate was seen intra- and

perineurally in the radicular nerves (**Figure 3A-B**), with decreasing intensity in the cervical to lumbar direction.

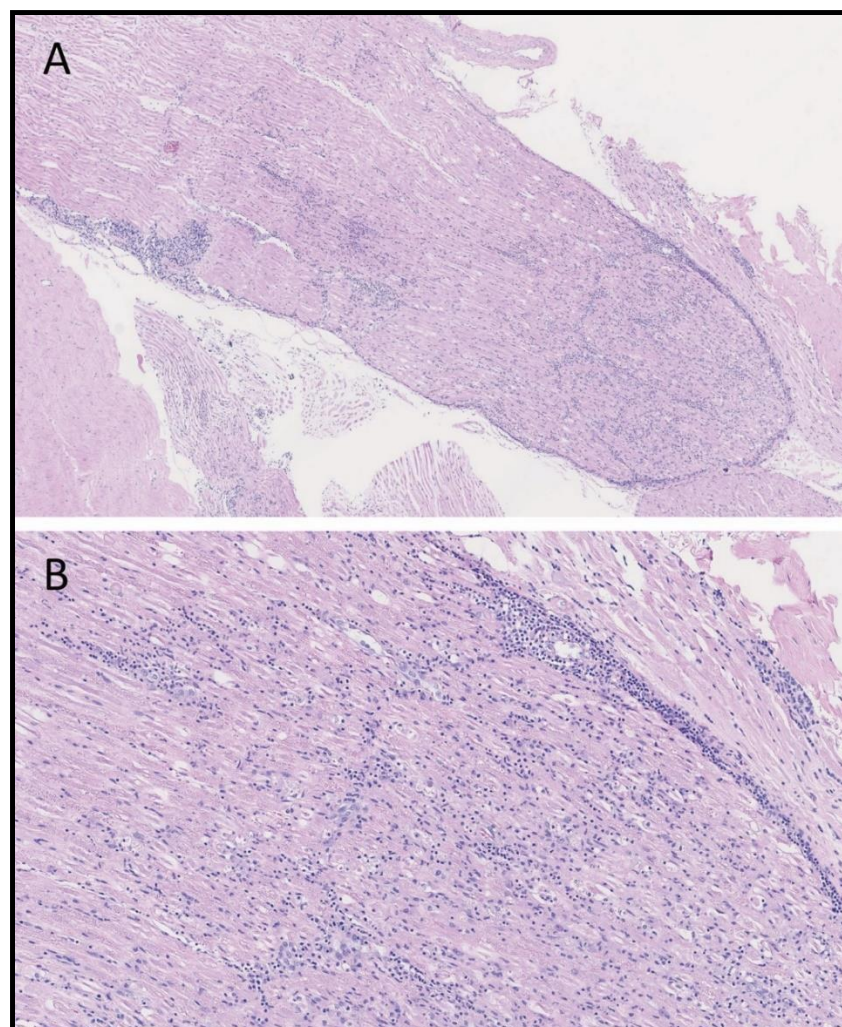


Figure 3. Histopathological images of the radicular nerve: Dense lymphoid infiltrates intra- and perineurally.
 A. Routine staining HE, 50 x magnification
 B. Routine staining HE, 100 x magnification

In the spinal cord isolated lymphoid infiltrates were found, especially in perivascular spaces. In the axillary nerves, a loose lymphatic cell infiltrate was seen, which was also partly detectable perineurally. Immunohistochemically, the lymphoid infiltrates in the brain and nerves were of T-cell phenotype, CD3 positive and CD20 negative. CD4-positive cells were predominant among the T lymphocytes, with a few CD8-positive cells present as well (**Figure 4A-B**). Staining with monoclonal J2 antibody (J2 anti-dsRNA IgG2a monoclonal antibody, SCICONS, English and Scientific Consulting) for detection of double-stranded viral RNA showed positivity in the brain and nervous

system, best demonstrated in the medulla oblongata's inferior olive neurons. Immunohistochemical staining with SARS-CoV-2 antibody (SARS Nucleocapsid protein antibody, NB100-56576, Novus Biologicals), to visualize the nucleocapsid protein was similarly positive within the same neurons (**Figure 5A-B**).

In addition to T cells found in the central nervous system, focal T cell infiltrates were also seen in the liver, pancreas, and kidneys.

In summary, both acute liver failure and vasculitis-like changes with fresh cerebral infarcts were causes of death. Myeloradiculitis and encephalitis were considered to have contributed to the death.

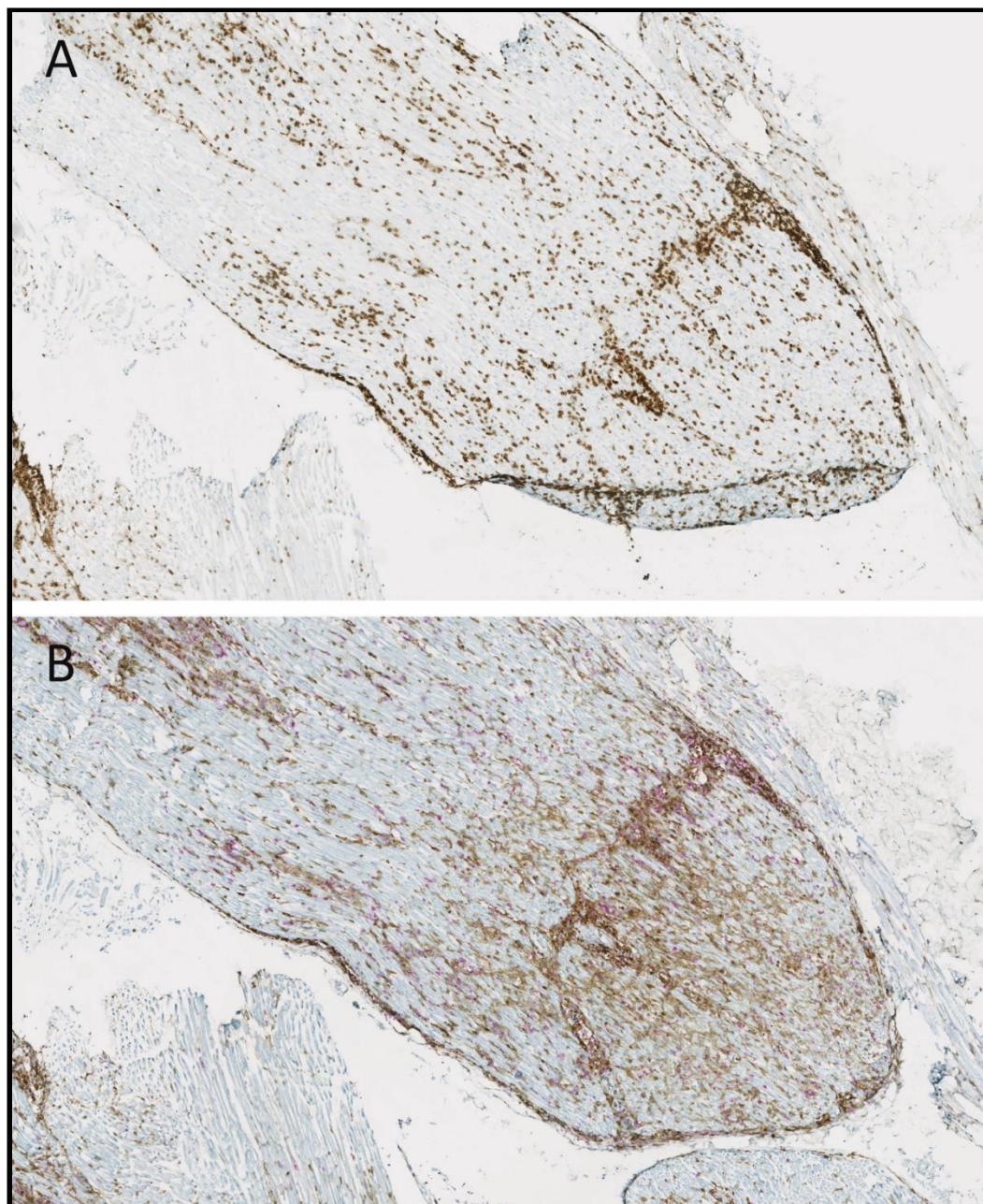


Figure 4. Histopathological images of the radicular nerve: Lymphocytes immunologically of T cell phenotype.

A. Immunological staining against CD3 (brown), 70 x magnification

B. Immunological double staining against CD4 (brown) and CD8 (red), 70 x magnification

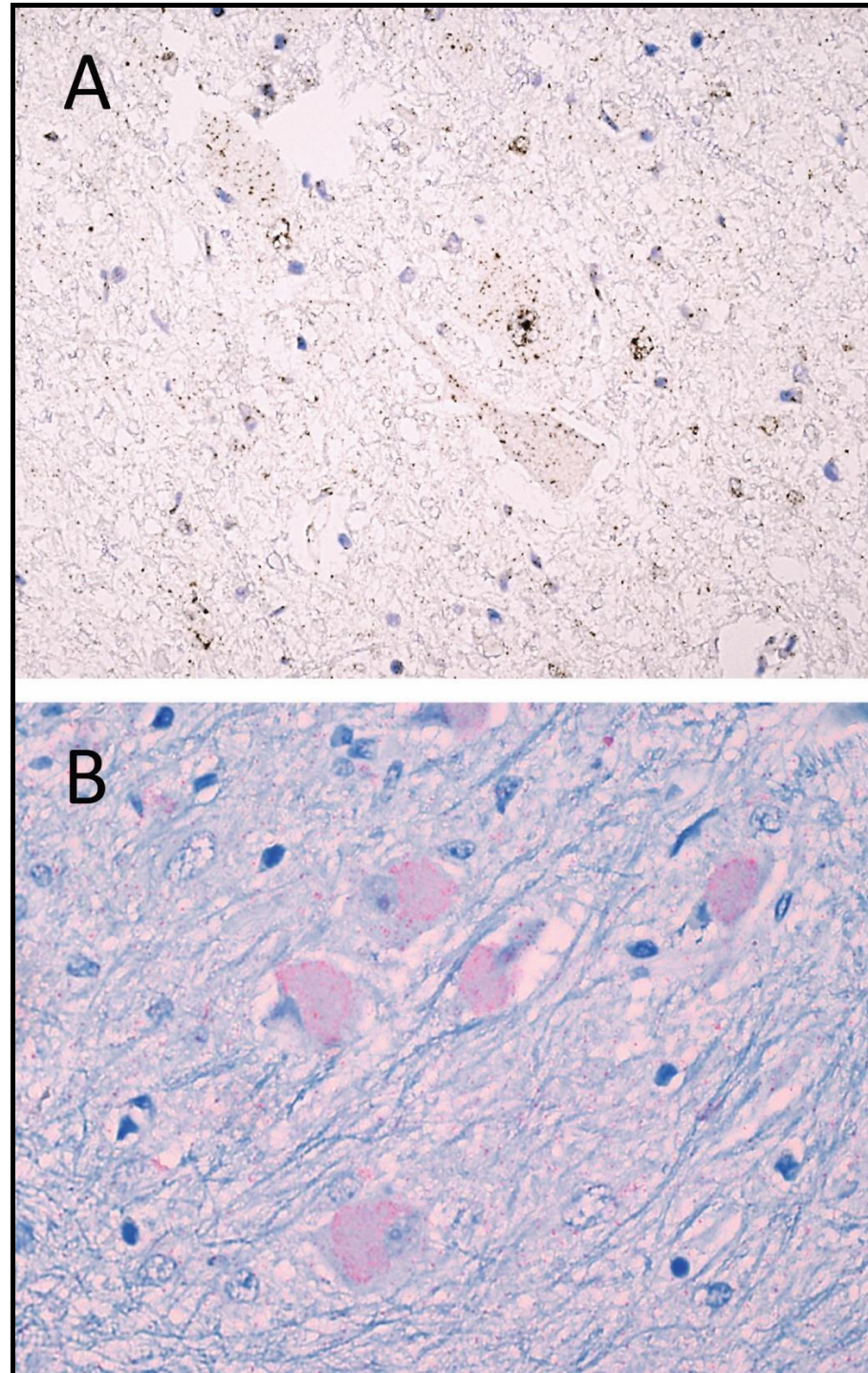


Figure 5. Histopathological images of the medulla oblongata, the inferior olive nucleus:

Positivity against double-stranded viral RNA J2 and nucleocapsid protein antibody SARS-CoV-2 accumulated in the neurons.

A. Immunological staining J2 (brown), 600 x magnification

B. Immunological staining SARS-CoV-2 (red), 600 x magnification

Differential Diagnosis

Clinically, physicians first suspected a paraneoplastic GBS. However, there was no evidence of this in the clinical course or at autopsy with subsequent microscopic analysis.

Treatment

In the two years before the patient's death, his known B-cell lymphoma was recurrently treated. Six months before death, the patient received renewed chemotherapy treatments due to lymphoma recurrence, combining cyclophosphamide, doxorubicin, vincristine, prednisone, and rituximab in more than half of the treatment cycles. Between two cytostatic treatments, the patient received two Pfizer/BioNTech vaccine doses, batch numbers EW5279 and

Discussion and Conclusion

In this complex case, a vaccination against SARS-CoV-2 was administered in temporal association with chemotherapy in combination with rituximab. Vaccinations have long been suspected

FA8016, with a one-month interval between them. In the last month of hospitalization before death, physicians performed several ascites punctures on the patient, on some occasions draining up to 6 liters of fluid.

The patient also received a few plasmapheresis treatments during the final phase. However, this only minimally improved the neurological symptoms.

Outcome And Follow-Up

The patient died one month after his last chemotherapy in combination with rituximab and three months after his second vaccination against SARS-CoV-2.

to contribute to the onset of autoimmune diseases [14], such as GBS or vasculitis.

Guillain-Barré syndrome is a rare, potentially fatal neurological disease, also known as polyradiculoneuritis. It is reported to have an

incidence of about 1/100,000 [15]. The disease is seen as a result of bacterial infection [16], such as *Campylobacter* [17] or *Mycoplasma* [18], or viral infection, like influenza [19], cytomegalovirus [20], Epstein-Barr virus [21], and SARS-CoV-2 [22], among others.

In addition, GBS is known to occur after vaccination [23]. Researchers have reported an association between the disease and vaccinations against influenza A [24], hepatitis B [25], combined tetanus-diphtheria [26], and now SARS-CoV-2 [2,3].

Furthermore, reports indicate a cerebral vasculitis-like pattern associated with GBS caused by SARS-CoV-2 infection [27].

Vasculitis after vaccinations have also been described in numerous cases, for example after vaccination against hepatitis B [28], influenza [29], hepatitis A [30], meningococci [31], anthrax [32], and herpes zoster [33]. With the introduction of the new vaccines against SARS-CoV-2, several case reports have been published in recent months. These are primarily cases of cutaneous vasculitis [4-8]. Anti-neutrophil cytoplasmic antibody (ANCA)-associated glomerulonephritis [9], vasculitis combined with Sweet syndrome [10] and Henoch-Schönlein purpura [11,12] have been described. Furthermore, there is one case description of intracerebral hemorrhage in vasculitis after SARS-CoV-2 vaccination [13].

Acknowledgments: None.

Abbreviations

GBS	Guillain-Barré Syndrome
SARS-CoV2	Severe acute respiratory syndrome coronavirus 2
CD20	Cluster of differentiation 20
CD3	Cluster of differentiation 3
CD4	Cluster of differentiation 4
CD8	Cluster of differentiation 8
ANCA	Anti-neutrophil cytoplasmic antibody
COVID19	Coronavirus disease 2019

References

- Bruchfeld A, Kronbichler A, Alberici F, Fervenza FC, Jayne DRW, et al. (2021) COVID-19 and ANCA-associated vasculitis: recommendations for vaccine preparedness and the use of rituximab. *Nephrol Dial Transplant.* 36(9): 1758-1760.
- Allen CM, Ramsamy S, Tarr AW, Tighe PJ, Irving WL, et al. (2021) Guillain-Barre Syndrome Variant Occurring after SARS-CoV-2 Vaccination. *Ann Neurol.* 90(2): 315-8.
- Finsterer J, Scorza FA, Scorza CA (2021) Post SARS-CoV-2 vaccination Guillain-Barre syndrome in 19 patients. *Clinics (Sao Paulo).* 76: e3286.
- Bencharattanaphakhi R, Rerknimitr P (2021) Sinovac COVID-19 vaccine-induced cutaneous leukocytoclastic vasculitis. *JAAD Case Rep.* 18: 1-3.
- Shahriharahkoshan S, Gagnon LP, Mathieu S (2021) Cutaneous Leukocytoclastic Vasculitis Induction Following ChAdOx1 nCoV-19 Vaccine. *Cureus.* 13(10): e19005.
- Grossman ME, Appel G, Little AJ, Ko CJ (2022) Post-COVID-19 vaccination IgA vasculitis in an adult. *J Cutan Pathol.* 49(4): 385-387.
- Berry CT, Eliliwi M, Gallagher S, Panaccione S, Klein WM, et al. (2021) Cutaneous small vessel vasculitis following single-dose Janssen Ad26.COV2.S vaccination. *JAAD Case Rep.* 15: 11-4.
- Kharkar V, Vishwanath T, Mahajan S, Joshi R, Gole P (2021) Asymmetrical cutaneous vasculitis following COVID-19 vaccination with unusual eosinophil preponderance. *Clin Exp Dermatol.* 46(8): 1596-7.

In the present case, the histopathologic correlation to GBS has marked radiculitis and less pronounced myeloencephalitis and neuritis. Cerebral vasculitis-like changes were also found, with acute cerebral infarcts contributing to death, including an infarct within the medulla oblongata, where SARS-CoV2 antibody staining revealed intraneuronal positivity. At present, it is unclear whether this virus was pathogenetic or a mere passenger in this case. Previous work has shown intraneuronal SARS-CoV-2 in individuals dying from COVID-19 and exhibiting neurological symptoms of varying degrees of severity [34].

The liver failure and necrosis which contributed to the patient's death can most likely be attributed to rituximab, following cases described in the literature [35]. During or after treatment with rituximab, viral infections can occur, some of which are serious [36].

It is currently unknown if any component of the vaccine, such as nanoparticles, affected the liver as well.

Against this background, it is suggested that vaccination against viruses in immunocompromised individuals should be carefully evaluated and planned.

Authors' Contributions

UK performed the autopsy, took the photos and wrote the draft. EE helped with immunohistochemical staining against virus. HM and EE were consulted for the histological evaluation and revised this article. All authors read and approved the final manuscript.

Funding: None.

Availability of Data and Materials: More references and immunohistochemical control stainings.

Conflicts of Interests: The authors declare that they have no conflicts of interests.

Consent For Publication: Not fully applicable, the patient is deceased. Demographic details have been changed to prevent recognition.

9. Villa M, Díaz-Crespo F, Pérez de José A, Verdalles Ú, Verde E, et al. (2021) A case of ANCA-associated vasculitis after AZD1222 (Oxford-AstraZeneca) SARS-CoV-2 vaccination: casualty or causality? *Kidney Int.* 100(4): 937-938.
10. Kinariwalla N, London AO, Soliman YS, Niedt GW, Husain S, et al. (2022) A case of generalized Sweet syndrome with vasculitis triggered by recent COVID-19 vaccination. *JAAD Case Rep.* 19: 64-7.
11. Naitlho A, Lahlou W, Bourial A, Rais H, Ismaili N, et al. (2021) A Rare Case of Henoch-Schonlein Purpura Following a COVID-19 Vaccine-Case Report. *SN Compr Clin Med.* 3(12): 2618-2621.
12. Sirufo MM, Raggiunti M, Magnanimiti LM, Ginaldi L, De Martinis M (2021) Henoch-Schonlein Purpura Following the First Dose of COVID-19 Viral Vector Vaccine: A Case Report. *Vaccines (Basel).* 9(10): 1078.
13. Takeyama R, Fukuda K, Kouzaki Y, Koga T, Hayashi S, et al. (2021) Intracerebral hemorrhage due to vasculitis following COVID-19 vaccination: a case report. *Acta Neurochir (Wien).* 164(2): 543-547.
14. Toussiot E, Bereau M (2015) Vaccination and Induction of Autoimmune Diseases. *Inflamm Allergy Drug Targets.* 14(2): 94-8.
15. Sejvar JJ, Baughman AL, Wise M, Morgan OW (2011) Population incidence of Guillain-Barre syndrome: a systematic review and meta-analysis. *Neuroepidemiology.* 36(2): 123-33.
16. Grygorczuk S, Zajkowska J, Kondrusik M, Pancewicz S, Hermanowska-Szpakowicz T (2005) Guillain-Barre Syndrome and its association with infectious factors. *Neurol Neurochir Pol.* 39(3): 230-6.
17. Rees JH, Soudain SE, Gregson NA, Hughes RA (1995) *Campylobacter jejuni* infection and Guillain-Barre syndrome. *N Engl J Med.* 333(21): 1374-9.
18. Susuki K, Odaka M, Mori M, Hirata K, Yuki N (2004) Acute motor axonal neuropathy after *Mycoplasma* infection: Evidence of molecular mimicry. *Neurology.* 62(6): 949-56.
19. Vellozzi C, Iqbal S, Broder K (2014) Guillain-Barre syndrome, influenza, and influenza vaccination: the epidemiologic evidence. *Clin Infect Dis.* 58(8): 1149-55.
20. Mamishi S, Ashrafi MR, Mohammadi M, Zamani G, Pourakbari B, et al. (2021) Cytomegalovirus Infection and Guillain-Barre Syndrome: The First Case-Control Study in Iran. *Iran J Child Neurol.* 15(4): 35-41.
21. Wallace LA, English SW, Fugate JE, Tosh PK (2021) Acute Epstein-Barr virus infection presenting as Guillain-Barre syndrome. *IDCases.* 25: e01196.
22. Finsterer J, Scorza FA, Fiorini AC (2021) SARS-CoV-2-associated Guillain-Barre syndrome in 62 patients. *Eur J Neurol.* 28(1): e10-e2.
23. Haber P, Sejvar J, Mikaeloff Y, DeStefano F (2009) Vaccines and Guillain-Barre syndrome. *Drug Saf.* 32(4): 309-23.
24. Salmon DA, Proschan M, Forshee R, Gargiullo P, Bleser W, et al. (2013) Association between Guillain-Barre syndrome and influenza A (H1N1) 2009 monovalent inactivated vaccines in the USA: a meta-analysis. *Lancet.* 381(9876): 1461-8.
25. Sinsawaiwong S, Thampanitchawong P (2000) Guillain - Barre' syndrome following recombinant hepatitis B vaccine and literature review. *J Med Assoc Thai.* 83(9): 1124-6.
26. Bakshi R, Graves MC (1997) Guillain-Barre syndrome after combined tetanus-diphtheria toxoid vaccination. *J Neurol Sci.* 147(2): 201-2.
27. Colonna S, Sciumé L, Giarda F, Innocenti A, Beretta G, et al. (2020) Case Report: Postacute Rehabilitation of Guillain-Barre Syndrome and Cerebral Vasculitis-Like Pattern Accompanied by SARS-CoV-2 Infection. *Front Neurol.* 11: 602554.
28. Le Hello C, Cohen P, Bousser MG, Letellier P, Guillevin L (1999) Suspected hepatitis B vaccination related vasculitis. *J Rheumatol.* 26(1): 191-4.
29. Watanabe T (2017) Vasculitis Following Influenza Vaccination: A Review of the Literature. *Curr Rheumatol Rev.* 13(3): 188-96.
30. Helbling R, Lava SA, Simonetti GD, Camozzi P, Bianchetti MG, et al. (2016) Gallbladder and Pancreas in Henoch-Schonlein Purpura: Review of the Literature. *J Pediatr Gastroenterol Nutr.* 62(3): 457-61.
31. Velasco-Tamariz V, Prieto-Barríos M, Tous-Romero F, Palencia-Pérez SI, Postigo-Llorente C (2018) Urticarial vasculitis after meningococcal serogroup B vaccine in a 6-year-old girl. *Pediatr Dermatol.* 35(1): e64-e65.
32. Muniz AE (2003) Lymphocytic vasculitis associated with the anthrax vaccine: case report and review of anthrax vaccination. *J Emerg Med.* 25(3): 271-6.
33. Puram V, Lyon D, Skeik N (2019) A Unique Case Report on Hypersensitivity Vasculitis as an Allergic Reaction to the Herpes Zoster Vaccine. *Vasc Endovascular Surg.* 53(1): 75-78.
34. Bocci M, Oudenaarden C, Sàenz-Sardà X, Simrén J, Edén A, et al. (2021) Infection of Brain Pericytes Underlying Neuropathology of COVID-19 Patients. *Int J Mol Sci.* 22(21): 11622.
35. LiverTox: Clinical and Research Information on Drug-Induced Liver Injury. Bethesda (MD)2012.
36. Aksoy S, Harputluoglu H, Kilickap S, Dede DS, Dizdar O, et al. (2007) Rituximab-related viral infections in lymphoma patients. *Leuk Lymphoma.* 48(7): 1307-12.